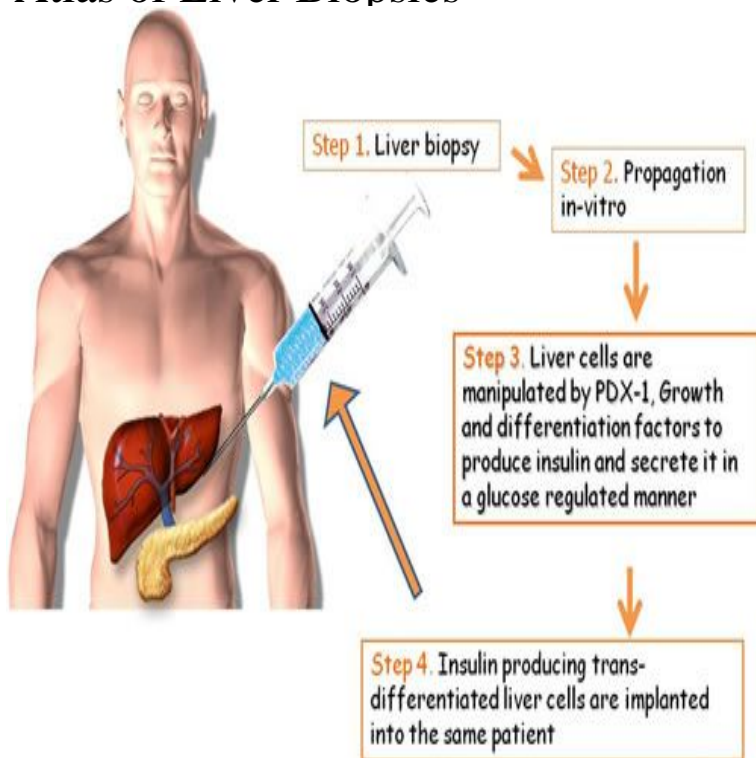


# Atlas of Liver Biopsies



Included in this atlas of liver biopsies are examples of common morphologic features of acute and chronic liver disorders, some involving the lobular areas ( e.g. A collection of photomicrographs, representing a variety of hepatic disorders, serves as the purpose of this small volume. The lesions constitute the range. Full text. Full text is available as a scanned copy of the original print version. Get a printable copy (PDF file) of the complete article (K), or click on a page. Atlas of Liver Biopsies [Hemming E. Poulsen] on balimedkarangasem.com \*FREE\* shipping on qualifying offers. Book by Hemming E. Poulsen. Needle biopsy of the liver is now an accepted procedure in most large hospitals, and surgeons and laparoscopists are more likely to biopsy the liver under direct. Chronic and excessive alcohol ingestion is one of the major causes of liver disease. The pathology of alcoholic liver disease consists of three. This novel approach to liver biopsy diagnosis combines color photomicrographs of common hepatic disorders with brief, descriptions of. The internist's role in liver biopsy should be more than securing a plug of tissue and reading the pathologist's report a few days later. If the procedure is to be of. This is a PDF-only article. The first page of the PDF of this article appears below. PDF extract preview. Request Permissions. If you wish to reuse any or all of this. Introduction. Examination of the Biopsy under the Light. 16 Pathology of the Liver Roderick N. M. MacSween. Snippet QR code for Atlas of liver biopsies. Liver Biopsy and Histopathological Diagnosis. Tadataka Yamada MD President Adjunct Professor<sup>2,3</sup>. Sugantha Govindarajan MD Professor. Atlas of Pathology for pregraduate students: microscopic and clinical images of Liver biopsy Liver, holes after needle biopsy, Macro, autopsy (). Liver Biopsy, An Atlas of Histologic Appearances: by R. G. Shorter, Senior Lecturer in Pathology, St. Thomas's Hospital Medical School, London. With an. Scanning electron microscopy in liver biopsy interpretation in children: a mini atlas. Cristina Mocci, Terenzio Congiu, Daniela Fanni, Clara Gerosa, Mina Komuta. Indications for liver biopsy in children are often specific to this age group, especially in young children for the diagnosis of cholestasis. Since liver biopsies are. Looking for liver disease in babies with intestinal failure on TPN: can ultrasound replace liver biopsy? In order to get proper nutrition to grow. 59 year on man on liver transplant list. Note biopsy tract is located in between two ribs, as the trajectory had to be through an intercostal space at the time of. Greenwald, R., Chiprut, R. O. and Schiff, E. R. (). Percutaneous aspiration liver biopsy using a large calibre disposable needle preliminary report. 6 Liver biopsy. Medical liver biopsy adequacy; Reporting .. Images: Hydatid cyst (balimedkarangasem.com) Hydatid cyst (balimedkarangasem.com) [1] Liver. Form to request liver biopsy for medical liver disease. Clinicopathologic correlation is crucial in the assessment of nonneoplastic liver disease. To ensure .

[\[PDF\] History of Indian Philosophy Volume 1](#)

[\[PDF\] Physics of the Solar System](#)

[\[PDF\] Christian Dior \(French Edition\)](#)

[\[PDF\] Parched](#)

[\[PDF\] Padded Pews or Open Doors](#)

[\[PDF\] Post-Marxist Theory: An Introduction \(S U N Y Series in Postmodern Culture\)](#)

[\[PDF\] Terminologia Medica Polyglotta: Medical Terminology in Six Languages](#)